

Steps for Examining the Oral Cavity in Elderly Patients With Dentures

*Raza Haque, MD, Division of Geriatrics, Department of Family Medicine, Michigan State University, East Lansing;
Danielle Watkins, DO, Family Medicine Residency Program, Sparrow Hospital, East Lansing, MI.*

Although oral health is known to be an important factor for optimal health and wellbeing for all older adults, it is often overlooked, placing this vulnerable population at risk for a variety of oral diseases (eg, periodontal disease) and systemic diseases (eg, cardiovascular disease, pneumonia). In many cases, it is assumed that dental health professionals are tending to the oral care needs of these patients; however, many older patients do not have dental insurance and do not seek care.

In 2011, the Institute of Medicine (IOM) published a report, “Improving Access to Oral Health Care for Vulnerable and Underserved Populations,” which examined oral care barriers for these and other at-risk populations (http://bit.ly/IOM_OralHealth_Report). One key barrier the IOM noted is the separation of oral healthcare from overall healthcare, which it suggested could be remedied by having nondental healthcare professionals, including physicians and nurses, step in to conduct regular oral health screenings.

Ideally, these screenings should be conducted in individuals who have their natural teeth, as well as those wearing removable dental devices (eg, full dentures, partial dentures), as these devices may lead to a false sense of security that the patient is receiving regular oral care. In addition, these devices can cause changes to the oral environment and tissues, particularly if they are not used correctly, placing these individuals at increased risk of various complications if the changes are not caught early.

Examining the Oral Cavity

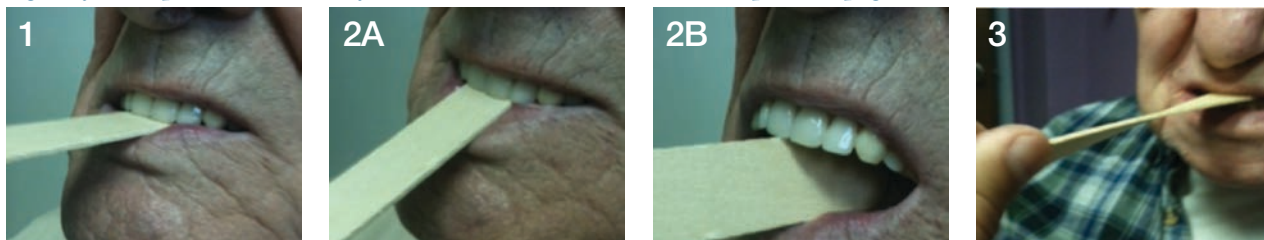
The oral cavity includes the lips, gingivae, retromolar trigone (ie, area behind the wisdom teeth), teeth, hard palate, cheek mucosa, mobile tongue, and floor of the mouth. Focused assessments of the oral cavity that examine each of these areas are essential, along with a brief swallowing test. This approach improves the chances of identifying potentially preventable or treatable oral health problems, which can lead to systemic illnesses. What follows are the procedures for conducting focused assessments of the oral cavity as well as the swallowing test in patients with dentures and other removable dental devices.

Step 1: Assess the Fit of the Dentures/Removable Devices

Before conducting oral health screenings in persons with dentures and other removable dental devices, ask what type they have (eg, full or partial dentures) and whether they have any concerns regarding these devices and/or their use. Next, follow these steps:

1. Inspect the patient's dentures/devices for general fit.
2. Ask the patient to bite upon a tongue blade placed flatly between the upper and lower incisors (**Figure 1**; see next page for all figures).
3. Try to gently pull the tongue blade (**Figure 2A**) and then turn it 90 degrees while the patient is keeping his/her bite fixed (**Figure 2B**).
 - a) Observe if the dentures are loose, as represented by easy displacement during this maneuver. If found to be loose, refer the patient for dental follow-up.
 - b) Observe if the dentures are too tight, as seen by difficulty moving the tongue blade when the patient has a firm bite (**Figure 3**). If too tight, a careful screening for any denture-related ulcers along the denture line of contact with the gums is warranted.

Figures for “Step 1: Assess the Fit of the Dentures/Removable Devices” on previous page



Step 2: Assess the Oral Cavity Without Dentures

1. Ask the patient to remove the dentures for inspection and observe his/her ability to perform this task.
 - a) *No trouble removing dentures:* No intervention is required for this task; however, this ability should be regularly assessed, as an older patient’s capabilities may change over time.
 - b) *Trouble removing dentures:* Provide assistance and determine whether the patient has resources available to assist with this task. If not, caregiver support should be sought/recommended.
2. Examine the patient’s gum lines and palate for denture-related stomatitis, hyperemia, or abscess, and then check the remaining oral cavity for any abnormalities, such as hyper- and hyposalivation; address any noted abnormalities. *Note:* A relatively whitish area on the palate or gum line in the region of contact may indicate that the patient’s dentures are too tight.
3. Ask the patient to place the dentures back in his/her mouth and observe the patient’s ability to perform this task.
 - a) *No trouble reinserting dentures:* No intervention is required for this task; however, this ability should be regularly assessed, as an older patient’s capabilities may change over time.
 - b) *Trouble reinserting dentures:* Provide assistance and determine whether the patient has resources available to assist with this task. If not, caregiver support should be sought/recommended.

Step 3: Perform the Brief Swallowing Test

1. Ask the patient to sip and hold approximately 15 mL to 20 mL of water in his/her mouth while he/she is in an upright sitting position.
2. Ask the patient to swish thoroughly and then swallow, while observing his/her ability to effectively complete the swallowing process.
3. Wait for any cough reflex, which can occur immediately or after a delay of 30 to 40 seconds.
 - a) *Immediate cough:* Repeat this maneuver without dentures. If no choking or coughing occurs without dentures, then denture-related aspiration is possible and the patient should be advised to have a dental follow-up as a precautionary measure. If the immediate cough occurs even without dentures, the patient may have a significant swallowing problem and further evaluation is warranted.
 - b) *Delayed mild cough:* A cough delayed by more than 30 seconds after testing is not uncommon and usually does not warrant any immediate intervention.